



## Summary Feedback

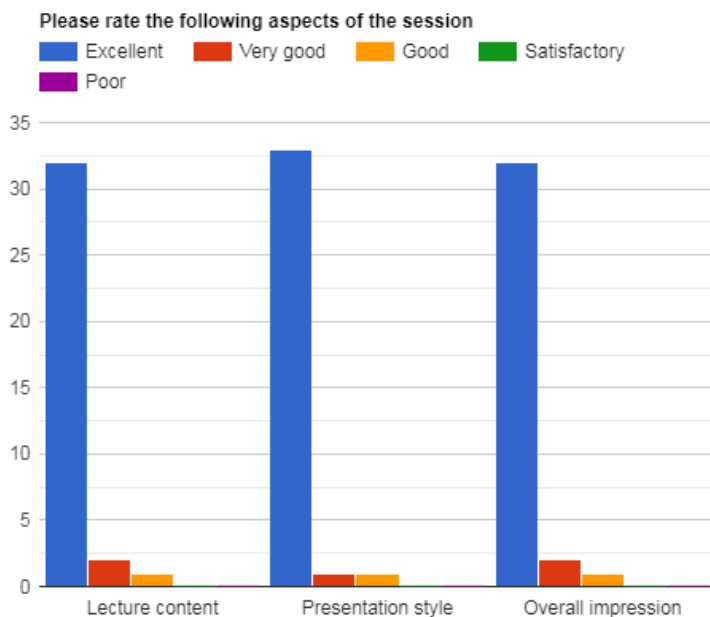
(Combined feedback broadcasted at multiple times this week)

### PRE - RECORDED ST1-ST4 Teaching Programme 2023

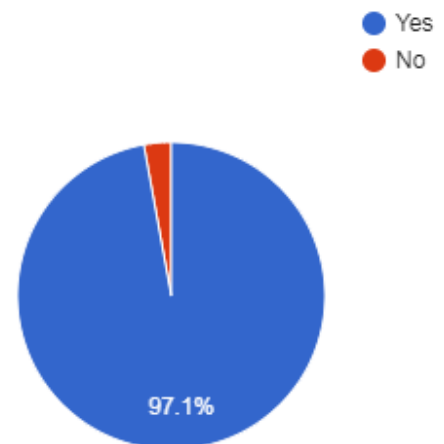
## GIT - (1) Oesophagus (2) CT of Carcinoma Oesophagus: Practice Cases (22<sup>nd</sup> and 23<sup>rd</sup> July 2023) Lecturer: Sami Khan

### Summary Points:

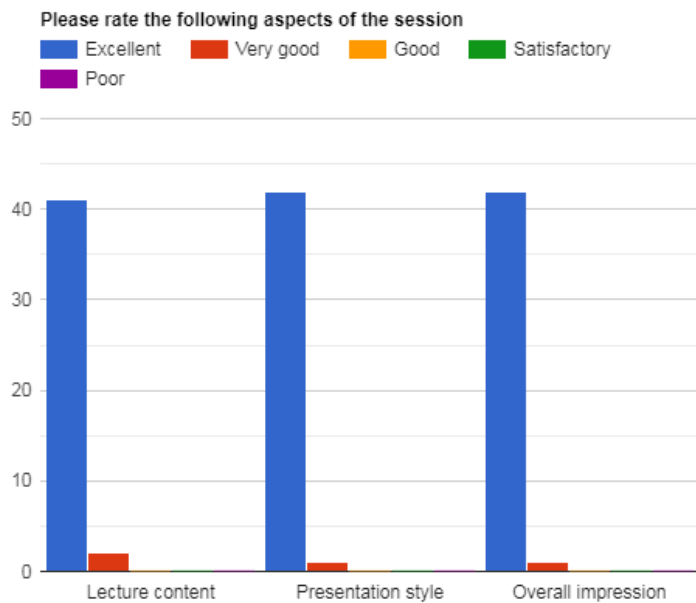
- Total Attendees: 231 from 28 Countries (China, Dominica, Egypt, Ghana, India, Indonesia, Iraq, Ireland, Kenya, Malaysia, Nepal, Nigeria, Oman, Pakistan, Qatar, Saudi Arabia, Singapore, South Africa, Sri Lanka, Sudan, Swaziland, Tanzania, Türkiye, UAE, UK, Yemen, Zambia, Zimbabwe).
- Total duration: 3 hours (each session broadcasted thrice during the week)
- Total feedback received from 82 participants, from three different broadcasts



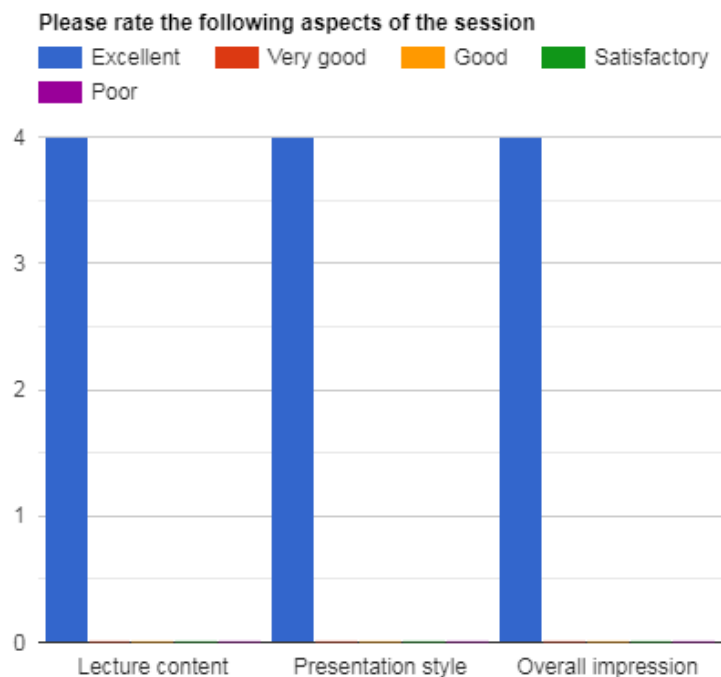
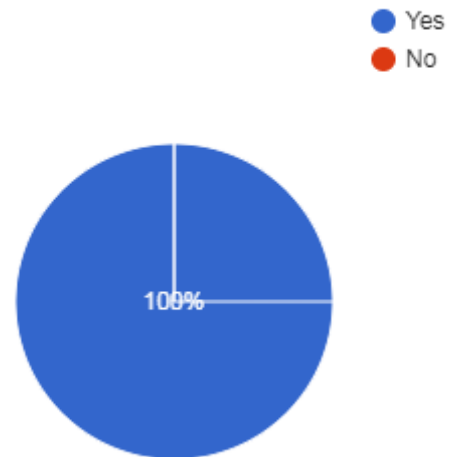
Did you find it useful  
35 responses



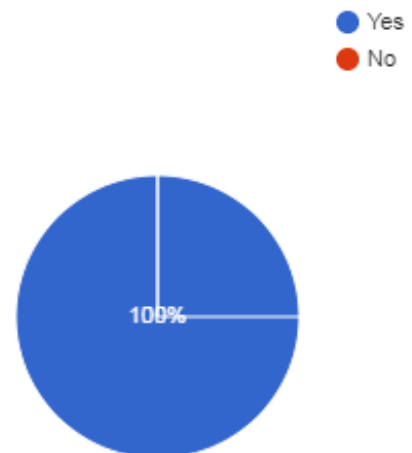
## GIT - (1) Oesophagus (2) CT of Carcinoma Oesophagus: Practice Cases



Did you find it useful  
43 responses



Did you find it useful  
4 responses



### Testimonials

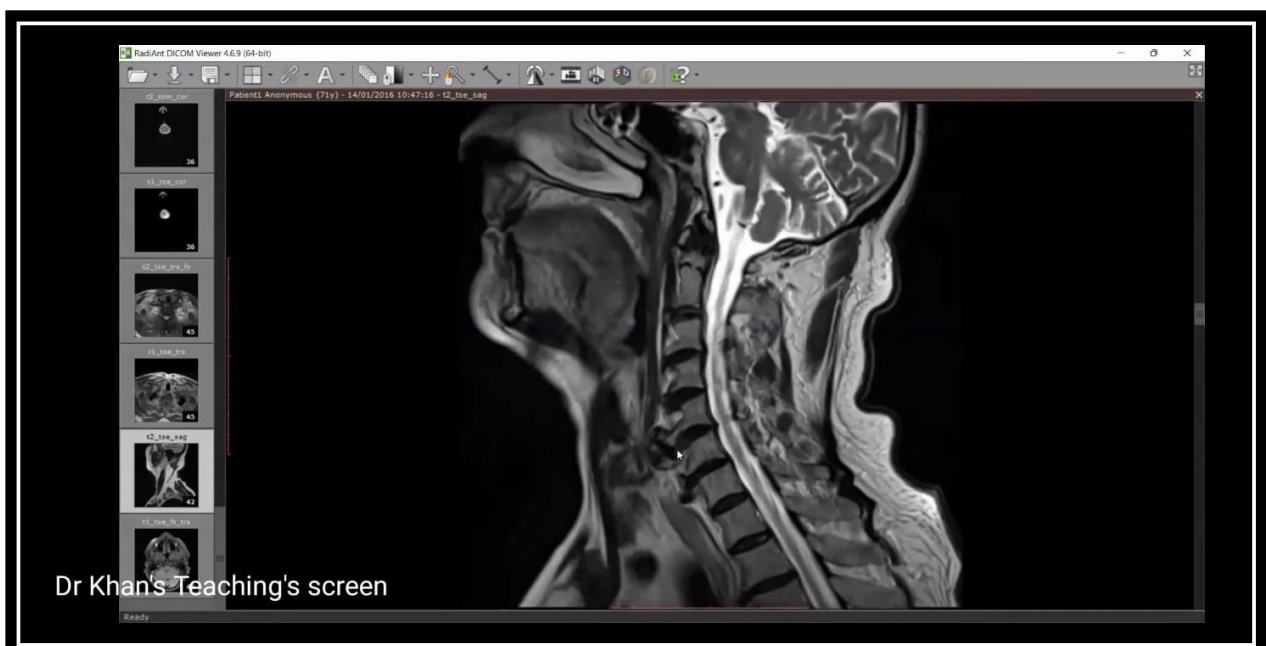
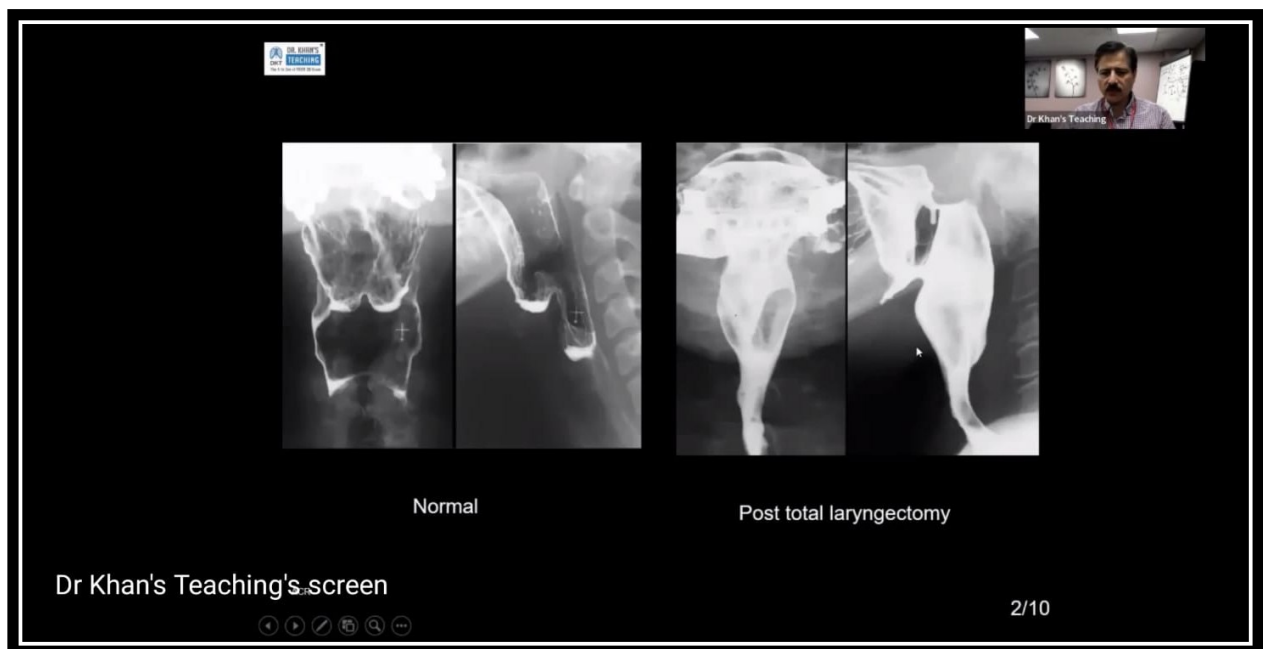
- Excellent teaching by Dr Khan, as always. He makes radiology interesting (UK).
- As always it's a blessing to have a dedicated teacher who is striving to deliver the best. Lots of prayers for your efforts (Pakistan).
- Dr Khan makes radiology look easy (Zimbabwe).
- Excellent overview of esophageal pathology and also staging of esophageal cancer which is a topic I needed to learn about (India).

## GIT - (1) Oesophagus (2) CT of Carcinoma Oesophagus: Practice Cases

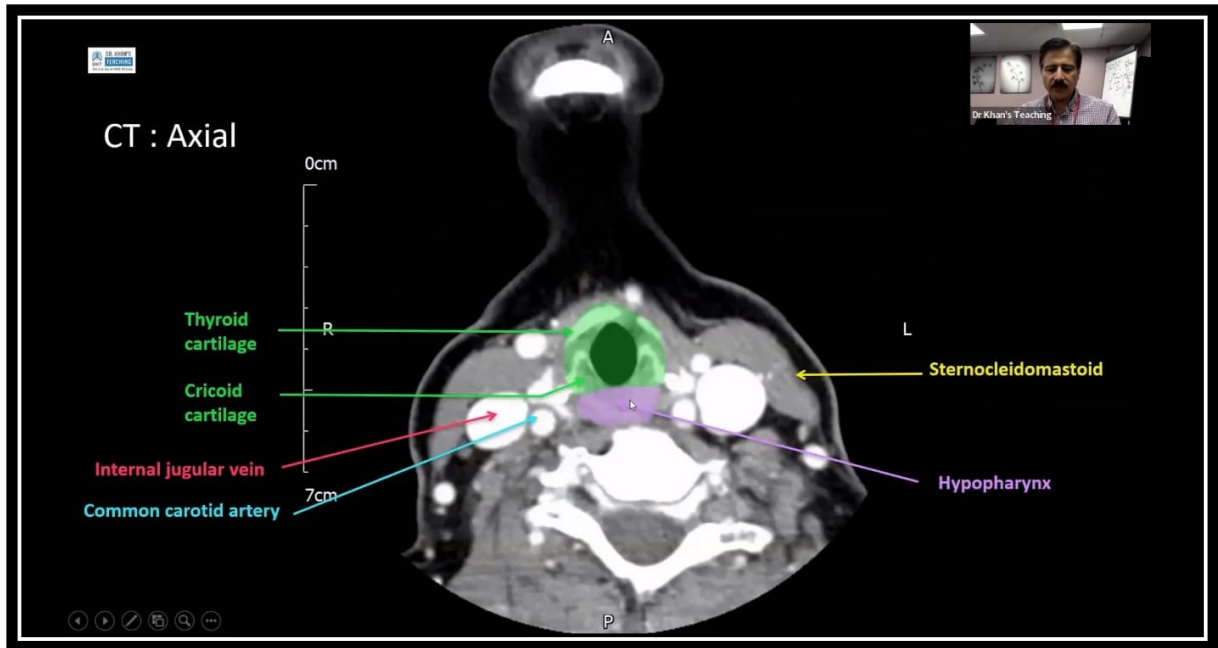
- The anatomy mixed with pathology teaching was very valuable. Makes it easy to spot the pathology (UK).
- Everything is superb (India).
- Excellent teaching session (Algeria).
- Perfect (UK).
- Outstanding (Pakistan).
- Superb Teaching (Pakistan).
- Beautiful explanation of cervical anatomy, barium studies for the esophagus and esophageal carcinoma T4 staging explained concisely (UK).
- Interaction with candidates, patience with explanation and attention to details were the best aspects (Nigeria).
- Excellent variety of clinical cases with important clinical findings (UK).
- All aspects were useful even though it was my 2nd time listening to the teaching (Malaysia).
- Great (UK).
- Very impressed (UK).
- Superb. second to none (UK).
- Awesome (Indonesia).
- Excellent teaching! (Malaysia).
- Excellent, fantastic (India).
- Very helpful before starting my GI placement, and very relevant for exam revision. Thank you! (UK).
- Amazing work (Pakistan).
- Best session (Pakistan).
- Detailed anatomy. Considerate teacher (Pakistan).
- Clear concepts (Pakistan).
- Impressive (UK).
- Brilliant (Pakistan).
- Excellent session (Pakistan).
- Very educational (Nigeria).
- Nice and well-done (Pakistan).
- Sir is the best (UAE).
- It's all excellent (Yemen).
- It's perfect (Pakistan).
- CT staging of esophageal CA and causes of esophageal narrowing were the most useful aspects (Zimbabwe).
- Images and the lecture were excellent (Pakistan).
- Excellent teaching material and teaching method (UAE).
- Impressive (Egypt).
- Excellent (Pakistan).
- Excellent session (Pakistan).
- Well-coordinated (Tanzania).
- Great knowledge (Pakistan).
- Useful (Pakistan).
- All of the lecture is superb (UK).

## GIT - (1) Oesophagus (2) CT of Carcinoma Oesophagus: Practice Cases

- Excellent explanation with pictures and clear pathology which are often difficult to visualize on mental picture (Sri Lanka).
- DICOM , anatomy and feedback reviews were the most useful (Algeria).
- Very informative session (Pakistan).
- Dr Khan's patient way of teaching and making sure our concepts get clear (Pakistan).
- Excellent session with good exam cases and explanation (Pakistan).
- All aspects were excellent, mind blowing, superbly covered and elaborated (Pakistan).
- Assessing degree of involvement and operability of esophageal carcinoma were really helpful (Sri Lanka).
- All aspects were useful, thanks to Dr Khan (Yemen).



GIT - (1) Oesophagus (2) CT of Carcinoma Oesophagus: Practice Cases



=====XX=====XX=====